

**CASE REPORT**

# Extracanalicular Osteoma of the Mastoid Region of Temporal Bone-A Rare Presentation

Sushil Kumar Aggarwal, Amit Keshri, Raj Kumar \*

**Abstract**

Extracanalicular temporal bone Osteomas are rare slow growing benign bone tumors of lamellar bone. Osteomas are commonly found in fronto-ethmoid region. In the temporal bone, they mostly occur in canalicular portion (EAC), but are very rare in extracanalicular portion of temporal bone. They are mostly asymptomatic and treatment is required mostly for cosmetic reasons. We report here an isolated case of extracanalicular osteoma of temporal bone due to its rarity in world literature and unusual site of presentation.

**Key Words**

Osteoma, Extracanalicular, Temporal bone

**Introduction**

Osteomas of temporal bone are rare, slow growing bone forming tumors (1, 2). The mastoid area of temporal bone is the most common site for extra-canalicular osteoma followed by squamous area and internal auditory canal (1, 2). These tumors are most often found in post-pubertal age and occur more commonly in women (1-4). They mostly present as cortical lesion giving rise to cosmetic deformity. When located in mastoid region, they are solitary, sessile or pedunculated and normally present as extra-cranial growth (3).

Our patient presented to us as a unique case of mastoid osteoma in a young adult male that was causing headache as patient was myopic and he had problems in wearing glasses. He also wanted to get it operated for cosmetic reasons.

**Case Report**

A 19 year old adult male presented to our tertiary care institute with a painless gradually progressive swelling in the left post-auricular area for 6 years (*Fig 1*). Swelling was gradually increasing in size and now had reached to a size of approx. 3 cm x 3cm. Since swelling was covering whole of the post-auricular region of temporal region, patient used to have headache as he was myopic and had problems while wearing spectacles. Patient wanted this swelling to be removed for cosmetic reasons also. On examination, the swelling was smooth and bony hard in nature; it was attached to the mastoid part of the temporal bone and the skin over the swelling was normal. Detailed ENT examination was done and it was

unremarkable. Seventh and eighth cranial nerves were normal on clinical examination.

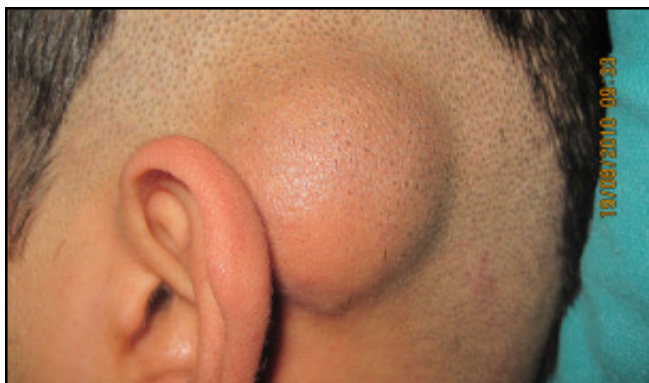We ordered axial and coronal cuts of high resolution CT scan of temporal bone to know the nature of swelling and its possible intracranial extension and to assess whether the swelling is isolated or multiple. On CT scan, the swelling appeared to arise from cortex of the bone and the swelling had inner fibrous core with outer bony covering (*Fig 2*). The CT scan findings were characteristic of osteoma. The patient was fully investigated and the posted for removal of post-auricular swelling under general anaesthesia. Skin incision was made and periosteal flap was elevated over the swelling. Tumor was freed all around of the periosteal flap and the tumor was removed enbloc using chisel and hammer. The residual margins were smoothed with the help of drill and the defect was covered with surgical hemostat. The incision was closed in two layers and pressure dressing applied. The excised specimen was sent for histopathological examination. On microscopy, the tumor sections showed mature lamellar bone surrounded by fibro-collagenous tissues consistent with the findings of compact osteoma. Patient is on regular follow-up for last 4 months now and is asymptomatic till date.

**Discussion**

Temporal bone osteomas are slow growing tumors whose exact etiology is still not known (5). Probably, they arise from preosseous connective tissues, most often localized at the suture line (6). A variety of theories inciting

From the (Neuro-Otology) & \*Deptt of Neurosurgery, SGPGIMS, Lucknow-226014- India

Correspondence to :Dr Sushil Kumar Aggarwal, Senior Resident (Neuro-Otology), Deptt of Neurosurgery, SGPGIMS, Lucknow-226014



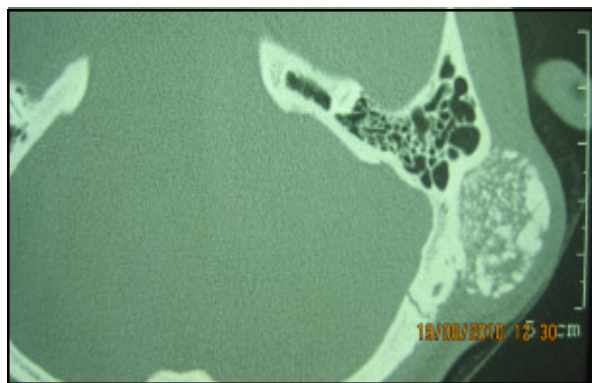
**Fig. 1 Patient Presenting with Left Mastoid Region Swelling**

their growth has been suggested from time to time including trauma with subsequent ossifying petrositis as suggested by Frieberg *et al.* (3). Other theories suggested include congenital mechanism<sup>7</sup> and pituitary influence.<sup>6</sup> These tumors are most often found in post- pubertal age and occur mostly in women (3) contrary to our case which was male.

Though the canalicular osteoma is common among this rare entity; extracanalicular osteomas are still very rare (1-4). They are slow growing and remain stable for many years (5). Superficially, they are smooth on palpation and have a characteristic bony hard consistency. Osteomas of mastoid region of temporal bone are typically solitary and pedunculated and they usually grow from outer cortex producing external swelling and hence cosmetic deformity (3). Osteomas of cranial bone are classified into four classes namely: Compact type which is the most common type and consists of compact and lamellar bone with few vessels and haversian system; those with dense bone are called as ivory osteoma; Cartilaginous type comprises of bony and cartilaginous elements; Spongy type is rare and composed of spongy bone and fibrous cell tissue with tendency to expand to diploe and thereby can involve the inner and outer lamina of involved bone. It has got bone marrow and hence known as osteoid or cancellous osteoma. The last type is mixed which is a mixture of spongy and compact types (8).

It is important to distinguish osteoma from other similar bony swellings like osteochondroma, exostosis and other benign bone tumors (9). CT scan is helpful in differentiating these tumors, although histopathological confirmation is also required. Exostosis lacks fibrovascular channels (9).

Osteomas are bony growths that are single, unilateral and pedunculated and mostly arise from tympanomastoid or tympanosquamous suture lines laterally (6) whereas exostoses are multiple, usually bilateral and broad based and are found medial to sutures of the temporal bone (10). Osteomas are generally asymptomatic. Sometimes,



**Fig. 2 Axial Cut of HRCT Temporal Bone Showing Bony Swelling Arising From Cortex of Left Mastoid Region**

they may give rise to headache when present in frontoethmoid region (11) contrary to our case in which headache was the presenting symptom even though the osteoma was on mastoid part. Asymptomatic osteomas warrant excision either for cosmetic purposes as they present with visible swelling outside or if the osteoma is pressing on some important structures leading to functional deficits.

#### References

- Denia A, Perez F, Canalis RR, Graham MD. Extracanalicular Osteoma of temporal bone. *Arch Otolaryngol* 1979; 105(2): 706-09.
- Cinelli AA. Osteoma eburnum of the mastoid. *Arch Otolaryngol* 1941; 33: 421-24.
- Freidberg SA. Osteoma of mastoid process. *Arch Otolaryngol* 1938; 28: 20-26.
- Fleming JP. Osteoma of the mastoid bone. *Canada J Surg* 1966; 9: 402-04.
- Vishwanath B. Extracanalicular osteoma of the temporal bone. *Ear Nose Throat J* 2008 ; 87 (7): 381-83.
- Yamasoba T, Harada T, Okuno T, Nomura Y. Osteoma of the middle ear: report of a case. *Arch Otolaryngol Head Neck Surg* 1990; 116(10): 1214-16.
- Stuart EA. Osteoma of mastoid: report of a case with investigation of the constitutional background. *Arch Otolaryngol* 1940; 31: 838.
- Morocco WA. Multiple Osteoma of mastoid cavity. *Arch Otolaryngol* 1948; 47: 673-77.
- Sheehy JJ. Diffuse exostoses and Osteomata of the external auditory canal: A report of 100 cases. *Otolaryngol Head Neck Surg* 1982; 90: 337-42.
- Fenton JE, Turner J, Fagan PA. A Histopathological review of temporal bone Exostosis and Osteoma. *Laryngoscope* 1996; 106: 624-28.
- Sente M, Topolac R, Peic Gavran K, Alaksov G. Frontal sinus Osteoma as a cause of purulent meningitis. *Med Pregl* 1999; 52(3-5): 169-72.